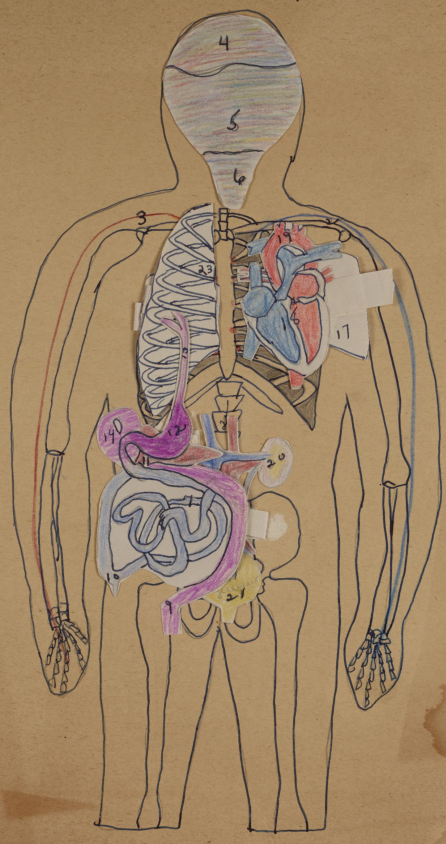


9a² La Dame Mayer

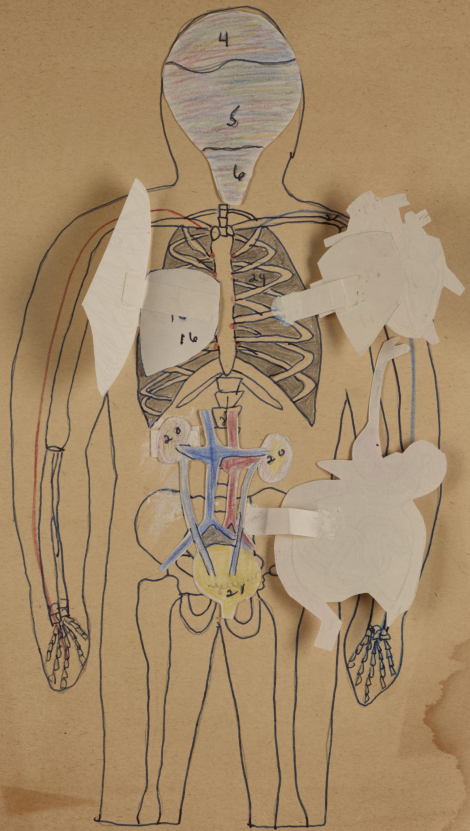
The Human Body

- | | |
|-----------------------|-----------------|
| 1. Ganglia | 23. Right rib |
| 2. Motor nerve | 24. Left rib |
| 3. Sensory | 25. Spinal cord |
| 4. cerebrum | } brain |
| 5. cerebellum | |
| 6. Medulla, oblongata | |
| 7. Large intestines | |
| 8. Small intestines | |
| 9. Colon | |
| 10. Appendix | |
| 11. Pancreas | |
| 12. Stomach | |
| 13. Esophagus | |
| 14. Liver | |
| 15. Gall bladder | |
| 16. Right lung | |
| 17. Left lung | |
| 18. Heart | |
| 19. Aorta | |
| 20. Kidney | |
| 21. Bladder | |
| 22. Uterus | |



The Human Body

- | | |
|-----------------------|-----------------|
| 1. Ganglia | 23. Right rib |
| 2. Motor nerve | 24. Left rib |
| 3. Sensory | 25. Spinal cord |
| 4. cerebrum } brain | |
| 5. cerebellum } | |
| 6. Medulla, oblongata | |
| 7. Large intestines | |
| 8. Small intestines | |
| 9. Colon | |
| 10. Appendix | |
| 11. Pancreas | |
| 12. Stomach | |
| 13. Esophagus | |
| 14. Liver | |
| 15. Gall bladder | |
| 16. Right lung | |
| 17. Left lung | |
| 18. Heart | |
| 19. Aorta | |
| 20. Kidney | |
| 21. Bladder | |
| 22. Uterus | |



1. Ganglia
2. Motor nerve
3. Sensory
4. cerebrum } brain
5. cerebellum }
6. Medulla, oblongata
7. Large intestines
8. Small intestines
9. Colon
10. Appendix
11. Pancreas
12. Stomach
13. Esophagus
14. Liver
15. Gall bladder
16. Right lung
17. Left lung
18. Heart
19. Aorta
20. Kidney
21. Bladder
22. Uterus

23. Right rib
24. Left rib
25. Spinal cord

The Human Body

